

## A Clinical Retrospective Evaluating Survival Rate and Success of Inclusive® Tapered Implants: An Analysis of Two-Year Results

### Introduction

Inclusive® Tapered Implants (Prismatik Dental Craft, Inc.; Irvine, Calif.) are indicated for use in maxillary and mandibular partially or fully edentulous cases, to support single, multiple-unit and overdenture restorations. The purpose of this study was to evaluate the efficacy of Inclusive Tapered Implants placed in human subjects using post-placement and post-restorative clinical observations collected over 24 months (Jan. 2010-Dec. 2012).

### Materials and Methods

This study is a retrospective evaluation of 167 Inclusive Tapered Implants placed at the Glidewell Laboratories operatory. The operatory clinicians were: Siamak Abai, DDS, MMedSc, Bradley C. Bockhorst, DMD, and Darrin M. Wiederhold, DMD, MS. Implants were placed in 54 male patients and 44 female patients. For some patients, treatment for more than one tooth was necessary; those patients received multiple implants.

Inclusive Tapered Implants were placed according to the standard surgical protocols detailed in the Inclusive Dental Implant System Surgical Manual. The single-stage protocol was followed for 107 procedures, and the two-stage protocol was followed for the remaining procedures. Patients were recalled for follow-up evaluations at various points in time in order to assess implant survival and success. After a healing period of four to six months, successfully integrated implants received their final restorations (Figs. 1-3).

### Results

Of the 167 implants placed, there were four surgical failures. Screw-retained restorations were placed on 151 implants, and cemented restorations were seated on the remaining implants. Implant survival rate was 97.6%. Implant failure rate was 2.4%.

### Conclusion

Inclusive Tapered Implants have been used to achieve positive surgical and restorative results (Fig. 4). Post-placement and post-restorative results show that Inclusive Tapered Implants demonstrate a survival rate of 97.6% in male and female patients.

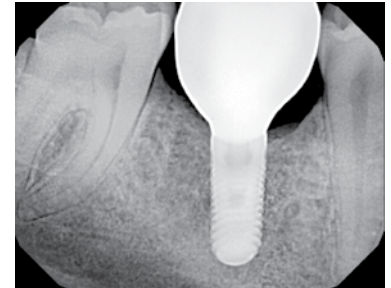


Figure 1: Successful integration of an Inclusive Tapered Implant six months post placement.

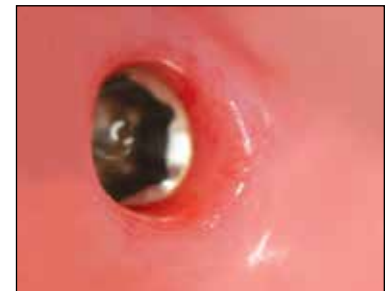

Figure 2: Soft tissue has successfully healed around an Inclusive Tapered Implant.

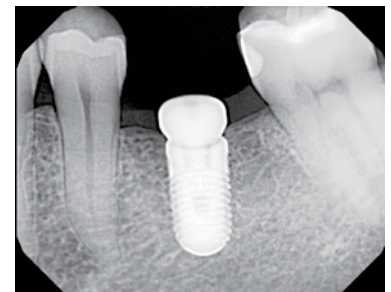


Figure 3: Radiograph shows another Inclusive Tapered Implant six months post placement with positive bone height after healing.

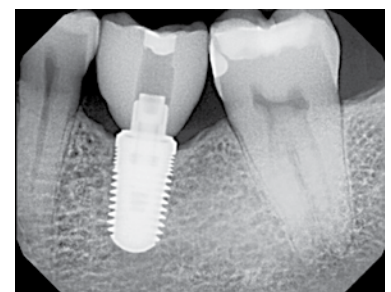


Figure 4: Radiograph at an 18 month recall appointment indicates that positive bone height has been maintained.